

# Dangerous and Under-Recognized Arteries of the Glabella—An Ultrasound Study of Central and Paracentral Arteries and Risk During Filler Injection

Robyn Siperstein, MD,\*† and Ahmad Nazari, MD, PhD‡

**BACKGROUND** Injecting fillers in the glabella is dangerous due to the presence of the central and paracentral arteries. These superficial arteries can connect to the ophthalmic artery putting patients at risk for blindness and stroke.

**OBJECTIVE** Determine the prevalence of the central and paracentral arteries (PCA) utilizing a portable ultrasound device.

**MATERIALS AND METHODS** A retrospective review of ultrasound data to determine the incidence and location of glabellar arteries at the level of the medial eyebrow in 29 Iranian subjects.

**RESULTS** The central and PCA were found on ultrasound in 26 and 36 of the 58 sides, respectively. The average distance from midline to the central and PCA was 4.1 mm (range 1.8–6.7 mm) and 8.2 mm (6.8–10.1 mm), respectively. The average depth from the skin to the central and PCA was 2.7 mm (2.2–3.2) and 3.0 mm (2.6–3.4 mm), respectively. Almost all patients (26/29) had at least 1 artery in the subcutaneous plane underlying the glabella. Increased body mass index resulted in increased arterial depth.

**CONCLUSION** Portable ultrasound was able to detect the central and paracentral arteries in most patients. Knowledge of the existence of these arteries and their subdermal location may be important to develop strategies to increase the safety of glabellar filler injections.

Treatment of glabellar lines with injectables was first reported in 1992 with botulinum toxin A.<sup>1</sup> Although this procedure is very effective for dynamic wrinkles and folds, patients often have resistant etched lines at rest. With repeated use of neurotoxin, these etched lines will continue to improve; however, complete resolution of deeper etched lines sometimes requires additional treatments.

There are many procedures that can treat resistant etched lines such as ablative and nonablative laser resurfacing, microneedling with or without radiofrequency, and chemical peels; however, full resolution of deep etched lines often requires significant downtime and cost utilizing the more intense treatments such as deep laser resurfacing or a deep chemical peel. Alternatively, a small amount of hyaluronic acid (HA) filler can be extremely effective for etched lines with limited downtime.

Although HA filler is a common treatment to fill folds and wrinkles all over the face, it is not approved by the Food

and Drug Administration for use in the United States in the glabella at this time. Hyaluronic acid fillers continue to grow in popularity, not only gaining new indications each year, but in addition, injectors are increasingly using HA “off-label,” despite not all areas being well suited for this treatment. Many practitioners are unaware of the anatomical difference in the arterial vasculature underlying many areas on the face and falsely assume that if lines in 1 area (perioral) are an approved indication, that there is the same risk profile and margin of safety for all areas on the face. In fact, a publication showing improvement in duration of effect of HA with botulinum toxin A versus botulinum toxin alone in glabellar rhytids did not even mention the anatomical danger of this area when recommending HA treatment for increased longevity.<sup>2</sup>

Unfortunately, the glabellar complex is a high-risk area due to many arteries lying close to the skin in this small space. Most experts believe that skin necrosis after filler is due to inadvertent injection into an artery leading to an obstruction. Although inflammation, spasm, platelet aggregation, and emboli can ensue and may also be responsible for tissue necrosis, ocular changes, and stroke,<sup>3</sup> the most likely first step is intra-arterial injection of filler.<sup>4</sup> Although some claim extravascular compression can be responsible, especially in small tight areas, studies have failed to reproduce vascular compression in animal models,<sup>5</sup> and a case report<sup>6</sup> showing compression with filler on ultrasound resulted in only tissue hypoperfusion and pallor, but not necrosis.

One reason the glabella is a high risk area is that most named arteries on the face lie either in the muscle or

From the \*Florida Atlantic University, Boca Raton, Florida; †Siperstein Dermatology Group, Boynton Beach, Florida; ‡iFACE Academy, Istanbul, Turkey

The authors have indicated no significant interest with commercial supporters.

Address correspondence and reprint requests to: Robyn Siperstein, MD, Florida Atlantic University, Boca Raton, FL 33431; Siperstein Dermatology Group, 9897 Hagen Ranch Road, Boynton Beach, FL 33437, or e-mail: DoctorSip@SipDerm.com  
Supplemental digital content is available for this article. Direct URL citations appear in the printed text and are provided in the HTML and PDF versions of this article on the journal's Web site ([www.dermatologicsurgery.org](http://www.dermatologicsurgery.org)).

© 2025 by the American Society for Dermatologic Surgery, Inc. Published by Wolters Kluwer Health, Inc. All rights reserved.  
Dermatol Surg 2025;00:1–7

<http://dx.doi.org/10.1097/DSS.0000000000004622>

underneath the muscle (facial, angular, transverse, infraorbital, zygomaticofacial, superior and inferior labial, deep temporal and zygomaticotemporal, etc.), whereas in the glabellar complex, the central artery (CA), paracentral artery (PCA), and superficial branches of the supratrochlear artery (ST) can be found in the subcutaneous plane. This is like other danger zones such as the nose (dorsal nasal artery [DNA]), upper forehead (ST), and temple (superficial temporal artery). In addition, the glabella is a small inflexible space with less subcutaneous tissue as compared to other areas,<sup>7</sup> which does not allow for a cannula to bend around the vessels.

In many publications, the glabella is reported as an area with a higher likelihood of vascular events leading to skin necrosis.<sup>8-10</sup> In fact, historically, the glabella was the most common area to experience this complication starting with collagen fillers. Hanke and colleagues<sup>11</sup> stated in 1991, that the rate of skin necrosis events reported to Collagen Corporation was 0.09% and that glabellar injections accounted for 56% of these cases. More recently with the advent of HA filler and changes to the popularity of certain injection locations, additional high-risk areas became evident such as the nose and nasolabial folds.

Published rates of vascular occlusions causing skin necrosis range from as high as 0.05% in a small retrospective study<sup>9</sup> to 0.002% utilizing cannulas in 1 survey of board-certified dermatologists<sup>10</sup> and 8.3% and 10.1% of these reported cases, respectively, occurred during injection into the glabella. Ozturk and colleagues<sup>8</sup> reported on a collection of 41 publications with 61 patients with severe complications and glabellar injections accounted for 23% (10/44) of the cases of skin necrosis.<sup>8</sup> Unfortunately, a study depicting the absolute risk of necrosis per syringe in each area is not possible because the total number of syringes injected each year is unknown, many occlusion cases go unreported, and 1 syringe is often injected in multiple locations.

Due to the anatomy of the area and proximity of the glabella to the ophthalmic artery (OA), there are numerous case reports<sup>12-22</sup> of blindness, and several large literature reviews describing these cases.<sup>8,23-26</sup> A review in 2013<sup>8</sup> reported that 50% (6/12) of the cases of vision loss came from glabellar filler injections, whereas a report in 2015<sup>23</sup> reported 38.8% of the 98 cases of blindness originated from glabellar filler. The most recent update<sup>26</sup> analyzed reports from 2019 to 2023 and found another 70 cases of blindness from glabellar filler alone in just 5 years. The reason glabellar filler is responsible for many of these cases is that the OA is the first branch of the internal carotid artery (ICA) and gives off many branches to both the glabella and the eye including the ST, DNA, and the central retinal artery (CRA). If filler enters the ST or DNA downstream with force, it can go retrograde and block the CRA. The most severe complications of glabellar vascular occlusions include scarring, blindness, and cerebral infarction. The latter 2 are due to the short distance from the glabella back to the CRA (measured as 5.2 cm<sup>27</sup>) and ICA, which supply the retina and the cerebral cortex, respectively.<sup>28</sup> To minimize

these serious complications, the anatomy of this area must be understood thoroughly before treatment.

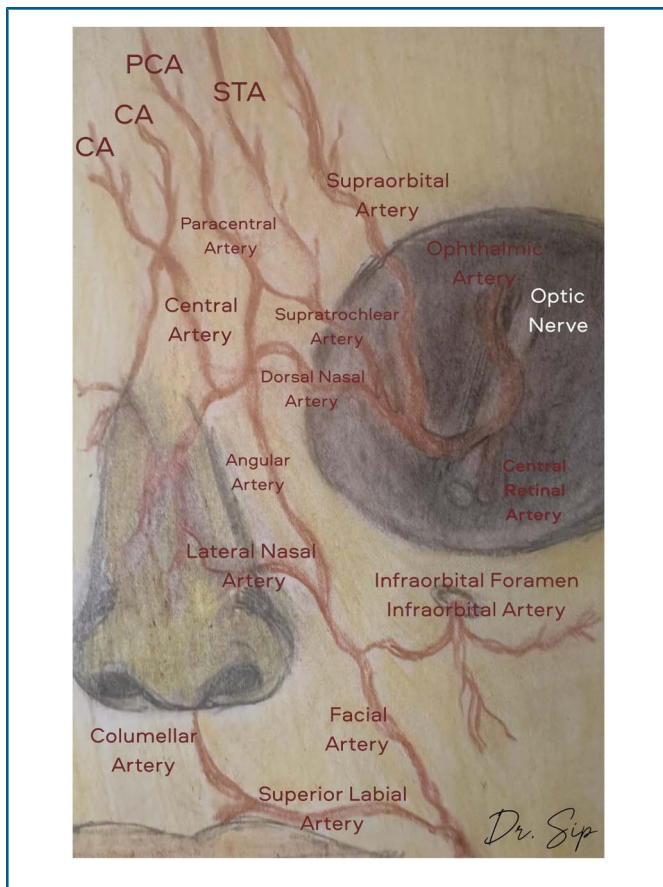
The anatomy in the glabellar area differs among individuals and even varies on each side of an individual. Most textbooks and publications show the angular artery (AA) continuing into the ST.<sup>29-31</sup> Although they certainly can anastomose and have communicating branches, this common rendition is confusing as the ST is a branch of the OA and comes from the ICA, whereas the AA comes from the external carotid system. In fact, in some people, the AA ends in the nose and does not ascend into the glabella.<sup>32-35</sup> When it ascends into the glabella, it usually continues as PCA and often anastomoses with the ST; however, the PCA is medial to the ST in the glabella. Another lesser-known artery that can occur in the glabella is the CA, most commonly an upward extension of the DNA. Although the PCA and CA are extremely important regarding the arterial blood supply of the glabella, unfortunately their presence is largely still ignored by anatomical textbooks and atlases.<sup>29,36</sup>

Without knowledge of the PCA and CA (Figure 1), practitioners are not aware to be cautious in this area. For example, many publications mention the detection of the ST with ultrasound is important for correction of glabellar frown lines without mentioning to check for any other more medial arteries that are more likely to be underlying the glabellar crease.<sup>30</sup> In fact, most publications assume the ST is the only artery of concern in the glabella<sup>13,37-39</sup> and, therefore, recommend a medial injection to avoid the ST without regard for medial vessels. One paper states that in 41 subjects, the average distance from the ST to glabellar line is about 1 cm, but stated it still was a danger zone without a proper explanation, other than vessels are variable instead of exploring more medial arteries closer to glabellar rhytids.<sup>37</sup>

In addition, most publications simply report any artery seen in the glabellar area on ultrasound simply as the ST,<sup>40-42</sup> without knowledge of its origin and correct nomenclature. Tansatit and colleagues<sup>43</sup> state that “ultrasound has limitations to trace the arterial courses compared to dissection...the PCA was not discriminated from the ST” in almost all ultrasound studies examining the glabellar arteries such as Lee and colleagues.<sup>42</sup> This leads to incorrect education on the dangers of the entire glabellar complex as most practitioners then assume if they avoid the ST they are safe. Although the PCA and CA may not be present in all people and ultrasound may not detect them in all cases, injectors should be educated about their possible existence and most common depth and location to understand that the subcutaneous space in the glabellar area near the rhytids could be high risk in some individuals.

## Materials and Methods

A retrospective review of ultrasound (Clarius LD20 HD3) data by the second author was done on 29 patient charts. The patients had previously visited a private clinic in Tehran, Iran for an educational course that observed vascular anatomy using ultrasound and no therapeutic



**Figure 1.** Rendering of glabellar arteries.

interventions were performed. All patients had provided informed consent, which included detailed information about the use of ultrasound and its safety. Subject data were excluded if any patients had any history of botulinum toxin A or filler injections into the glabellar area, or a history of any facial surgery, trauma, or congenital structural issues. The principles of the 1975 Declaration of Helsinki were followed.

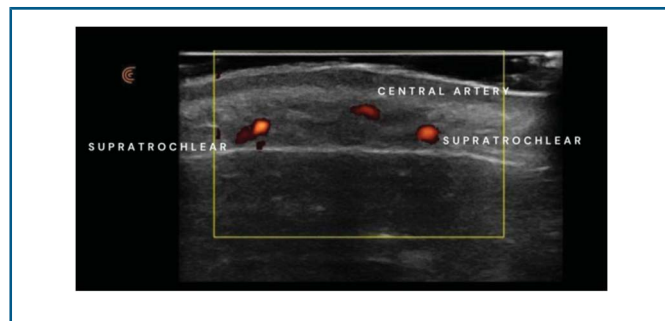The data extracted included the depth of any paracentral or central arteries found with a portable ultrasound and their distance from midline. These data were obtained when the ultrasound probe was in between the head of the eyebrows.

## Results

There were 17 (58.6%) female and 12 (41.4%) male charts reviewed. The mean age of the patients was 37 years old (range 21–64, SD 10.5 years). The mean body mass index (BMI) was 27.3 (range 23.5–32.4, SD 2.1). Arteries in the intercanthal central zone (1 cm from midline on either side) were always in the subcutaneous plane as seen in Figures 2 and 3, and most patients (26/29) had at least one of these superficial arteries.

### Central Artery

The average distance from midline to the CA was 4.1 mm (range 1.8–6.7 mm, SD 1.1), whereas the average depth



**Figure 2.** Subdermal location of the CA. CA, central artery.

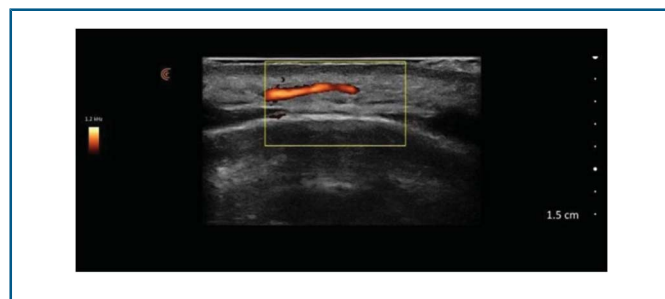from the skin to the CA was 2.7 mm (2.2–3.2, SD 0.28). There were differences in the presence of the artery between the patients' 2 sides, 14 had a CA on 1 side but not the other on ultrasound, 6 had both present, and 9 had none present on ultrasound. Overall, the CA was found on ultrasound in 26/58 sides, 12/29 on the right side and 14/29 on the left side. There was no significant difference in the CA on the left and right side regarding both the depth and distance from midline.

### Paracentral Artery

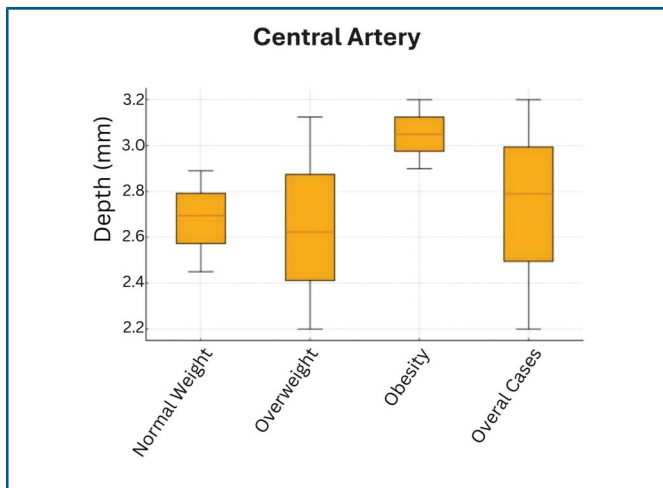
The average distance from the midline to the PCA was 8.2 mm (6.8–10.1 mm, SD 0.9), whereas the average depth from the skin to the PCA was 3.0 mm (2.4–3.5 mm, SD 0.25). There were differences between the patients' 2 sides, with 12 people having a PCA on 1 side but not the other. There were 12 patients that had a PCA on both sides and 5 with neither side showing 1 on ultrasound. Overall, the PCA was found in 36/58 sides, 17/29 on the right side and 19/29 on the left side. There was no significant difference in the PCA on the left and right side regarding both the depth and distance from midline.

### Secondary Variables

There was no difference in the distance from midline ( $p = .082$  right side,  $p = .482$  left side) and depth ( $p = .144$  right side and  $p = .30$  left side) of the PCA based on the presence or absence of the CA. Both the CA and PCA had a correlation of BMI to depth of the artery ( $p = .036$  and  $p = .019$ , respectively), Figures 4 and 5. The distribution of all arteries 1 cm from the midline is depicted in Figure 6.



**Figure 3.** Subdermal course of a PCA. PCA, paracentral artery.

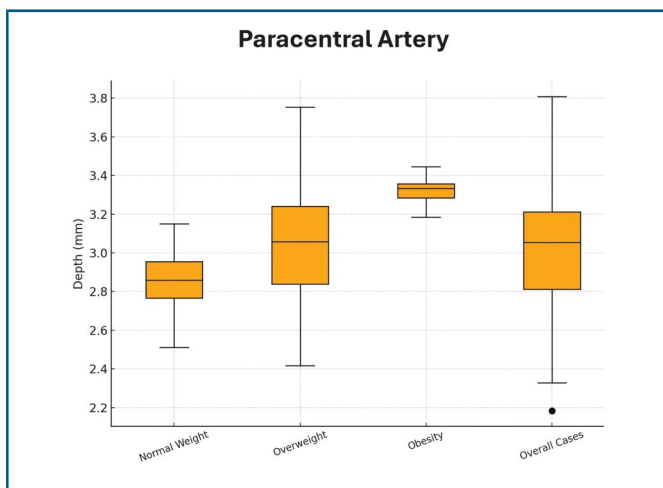


**Figure 4.** CA depth according to BMI. CA, central artery; BMI, body mass index.

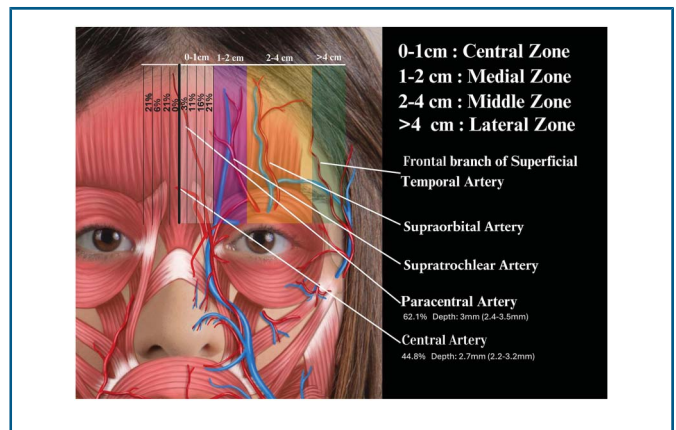
## Discussion

Shumrick and Campbell<sup>44</sup> and Vural and colleagues<sup>41</sup> were one of the first 2 groups to report on the glabellar arteries in 1998 and 2000, although for the purpose of paramedian forehead flaps.<sup>41</sup> They found that the average distance from the ST to the glabellar frown line was 17 to 22 mm in cadavers and 10.9 mm on ultrasound, respectively. In addition, Vural reported that the distance on ultrasound from the midline to the glabellar frown line was 9.3 mm, and that there was an artery present under the glabellar lines approximately 50% of the time.<sup>41</sup>

Kleintjes<sup>45</sup> then first coined the names PCA and CA in 2007 after reviewing 30 cadavers. He reported that the CA was consistently found in cadaver dissections originating from the DNA about 5 mm from its origin and average size was 1 mm. The CA had a constant anastomosis with the opposite CA in the lower forehead creating a triangle, but often stopped before reaching the upper forehead. He found the CA just as frequently as the ST. Kleintjes hypothesized that the reason the CA is not mentioned in many studies is



**Figure 5.** PCA depth according to BMI. PCA, paracentral artery; BMI, body mass index.



**Figure 6.** Location, percentage, and depth of arteries.

due to the origin not being visible if dissecting superficial to deep because the central vein is in front of it. Kleintjes found the PCA in 21 hemi-faces, usually as a continuation of the AA (15/21) up into the forehead medial to the ST, or from the communicating branch of the ST to the AA (6/21).

Cong and colleagues<sup>46</sup> reported in 2017 finding the PCA or CA in 20% of cadavers, although interestingly only when the ST supplied the deep aspect of the frontalis, and the PCA/CA supplied the superior aspect of the medial frontalis. In addition, 2/9 cadavers did not share the same arterial distribution on both sides and differed from left to right.

Koziej and colleagues<sup>47</sup> analyzed cadavers in 2019 using computed tomography angiography and found the ST in 97.3% measuring 1.4 mm in diameter and averaging 14 mm from midline. The PCA was found in 44% with a median diameter of 1.5 mm, 7.6 mm from midline, and originated from a communicating branch of the ST in 12/33 36.4% and from the AA in 63.6% (21/33). The CA network was found in 34.7%, but a distinctive artery was not easily visualized, which they thought was likely due to their imaging technique being insufficient for smaller arteries.

Phumyoo and colleagues<sup>48</sup> utilized both cadaver dissection and ultrasound to report that the CA was present in 42.1% of cadavers (16/38) as a branch of the DNA arising from the radix of the nose and was found on average 4.7 mm from the midline at a depth of 3.1 mm on ultrasound. The CA anastomosed with the contralateral artery in the glabellar region.<sup>48</sup> The PCA was found in cadaver dissection 21.1% (8/38) on average 7.8 mm from midline and on ultrasound at a depth of 4.8 mm. Finally, the ST was found in 89% (25/28), 14.7 mm from midline and on ultrasound measured 0.7 mm at an average depth of 4.2 mm.<sup>48</sup>

In 2020, Lee and colleagues<sup>42</sup> reported that among 74 glabellar wrinkles, 41% (30/74) had an artery underneath, whereas 59% (44/74) had an artery lateral to it. Cotofana and colleagues<sup>37</sup> reported the mean depth of the ST was 3.34 mm at rest; however, there was no mention of the central and paracentral arteries in that publication.

Tansatit and colleagues<sup>43</sup> reviewed 30 cadavers and reported in 2021 that the ST was found in 88% of cadavers,

whereas the PCA was found in 27%, with no mention of the CA as a separate artery. More importantly, the definition of the PCA in this paper (opposite direction of the DNA) is more similar to Kleintjes<sup>45</sup> definition of the CA confounding the data.

Park and colleagues<sup>49</sup> only found an artery on ultrasound 3% of the time (1/30) on the bottom of the glabellar region, but 36.4% of the time on the top of this area (8/22). Interestingly, most of the vessels they found in the glabellar region were veins, which were present in almost all subjects (29/30) and could have obscured arteries underneath. Guvenc and colleagues<sup>40</sup> later performed an ultrasound analysis tracking the ST in 71 cases. The distance between the epidermis and artery near the eyebrow was between 1.8 and 5.9 mm (mean 3.54) with a distance from the bone between 0.7 and 3.7 mm (mean 1.85). In patients with less body mass, the depth to the artery decreased.<sup>40</sup> Based on their findings, they recommend not injecting deeper than 1.8 mm, whereas Park and colleagues considered 1.6 mm and less the safe area.

The arterial system of the glabella is incredibly variable and complex as shown in Cai and colleagues<sup>50</sup> publication in 2021 of a new named arterial variant called the reverse dorsal nasal artery (rDNA) where the DNA was supplied from the external carotid system through the lateral nasal artery instead of from the internal carotid system from the OA. These variants of normal human anatomy make these danger zones even tougher to predict.

Liao and colleagues<sup>51</sup> wrote 2 recent papers acknowledging that “clinicians always ignore the important contributions of the CA and PCA to the blood supply of the glabella.” They used more advanced imaging with computed tomography of cadavers and found the CA, PCA, and rDNA in 38.9%, 32.2%, and 8.9% of the 180 hemifaces they analyzed between 1.1 and 3.9 mm depth in the subdermal plane.

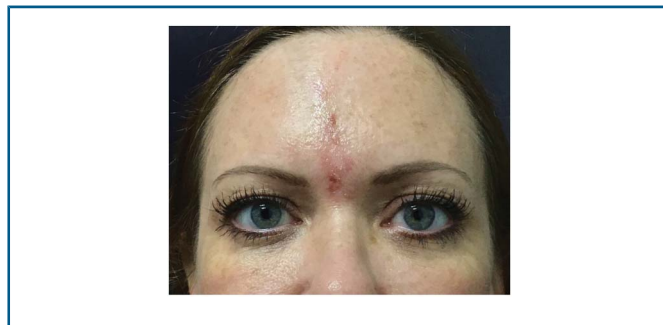Finally, Ismailoglu and colleagues<sup>52</sup> found similarly to Cai and colleagues<sup>50</sup> that the DNA is often supplied by the AA and they reported both the CA and PCA present together in 18.8% (3/16), both the CA and PCA absent in 12.5% (2/16), a CA present 56.2% (9/16) of the time located on average 1.8 mm from midline (0–3.9 mm), and a PCA present 43.7% (7/16) of the time located on average 6.2 mm from midline (3.5–9.3 mm). A summary is available (see **Supplemental Digital Content 1**, Table 1, <http://links.lww.com/DSS/B618>) describing all the anatomical findings from publications on glabellar artery anatomy. Most of the previous ultrasound studies reported that they assumed all vessels were the ST—“In this article we could not differentiate the paracentral artery or branches of the ST used simple terminology as most previous articles and we called the artery that we observed in glabellar region as ST.”<sup>40</sup> Although other studies seem oblivious to the presence of other named arteries in this area<sup>37–39</sup> and never mention them. In the literature, the PCA and CA are found in a percentage of cases; however, in many instances (especially ultrasound), it is difficult to distinguish between the PCA and the branches of the ST in the glabella, and they

simply refer to any artery observed in the glabellar region as the ST.<sup>40</sup>

Although most publications focus on the ST as the cause of complications with glabellar filler,<sup>13,37,49</sup> a few more recent papers<sup>43,47,51,53</sup> are starting to shift toward the realization there the more medial arteries in closer approximation to the glabellar lines are important and likely implicated in vascular occlusions in this area. The third region in Figure 6, which is 5 to 7.5 mm from midline, is typically where fillers are injected for glabellar rhytids, and although they have smaller frequency, both the PCA and CA can overlap in this region. Although these arteries are inconsistent, perhaps their presence in some leads to higher risk of vascular occlusion in certain individuals such as the patient in Figure 7. This patient had HA filler injected in her glabellar lines and experienced bilateral occlusion of the central arteries, which often appears as a “v” or diamond shape in the central glabella with impending necrosis superiorly due the watershed nature of these 2 vessels joining together and ending in the central forehead. This case among others<sup>16,54</sup> displays skin changes in the central glabella, distinctly medial to the ST, which often ascends from the medial eyebrow, signifying that the PCA and CA, and not the ST, are responsible. Although most publications discuss the retrograde flow of filler from the suprobital artery and ST to the OA as the cause of blindness,<sup>24</sup> the authors hypothesize that the PCA and CA are just as often implicated through direct connection with the ST and DNA, which are branches of the OA.

Although portable ultrasound is inexpensive, safe, quick, and noninvasive, it is prone to errors by those with less experience (pressing too hard constricting blood flow, unable to detect origin of artery, unable to pick up small arteries, etc.). In addition, in clinical practice it is often too time consuming and impractical for everyone to use during every injection; however, for those injecting high-risk areas such as the glabella, taking a few minutes to image those areas could be considered. In addition, knowing that those with a lower BMI may be more susceptible to this risk due to less distance from the skin to the artery is also important.

The importance of the CA and PCA extends beyond those performing cosmetic fillers to those executing forehead flaps. In fact, a study in 2016<sup>55</sup> that expected the classic paramedian flap found with ultrasound to contain



**Figure 7.** A 43-year-old woman with an occlusion of the central arteries several days after filler injection.

the ST to outperform a paramidline flap that was taken from the midline measuring laterally 1.2 cm had surprising results. They found that there were more arterial vessels in this midline area as described above (PCA and CA), which resulted in lower complications and better performance of the flap.

## Conclusion

Although Kleintjes<sup>45</sup> first coined the names paracentral and central arteries in a publication in 2006, most publications, textbooks, and atlases today still do not mention them.<sup>29–31,37,56</sup> Their absence needs to be rectified in the future as they are likely the cause of many vascular occlusions resulting in skin necrosis or blindness in this region. Without this information, some injectors may feel comfortable palpating for the supratrochlear notch and proceeding with glabellar filling medial, not realizing there are often other important large centrally located arteries medial to the orbital rim in most individuals. This study revealed that most patients (26/29) had at least 1 centrally located artery (PCA or CA) in the subdermal plane. This knowledge may be important to develop strategies to potentially prevent complications in the glabellar area.

## References

- Carruthers JD, Carruthers JA. Treatment of glabellar frown lines with C. botulinum-A exotoxin. *J Dermatol Surg Oncol* 1992;18:17–21.
- Dubina M, Tung R, Bolotin D, Mahoney AM, et al. Treatment of forehead/glabellar rhytide complex with combination botulinum toxin a and hyaluronic acid versus botulinum toxin A injection alone: a split-face, rater-blinded, randomized control trial. *J Cosmet Dermatol* 2013;12:261–6.
- Zhao F, Chen Y, He D, You X, et al. Disastrous cerebral and ocular vascular complications after cosmetic facial filler injections: a retrospective case series study. *Sci Rep* 2024;14:3495.
- King M, Walker L, Convery C, Davies E. Management of a vascular occlusion associated with cosmetic injections. *J Clin Aesthet Dermatol* 2020;13:E53–E58.
- Chang SH, Yousefi S, Qin J, Tarbet K, et al. External compression versus intravascular injection: a mechanistic animal model of filler-induced tissue ischemia. *Ophthalmic Plast Reconstr Surg* 2016;32:261–6.
- Lima VGdF, Regattieri NAT, Pompeu MF, Costa IMC. External vascular compression by hyaluronic acid filler documented with high-frequency ultrasound. *J Cosmet Dermatol* 2019;18:1629–31.
- Cha KS. Soft-tissue thickness of South Korean adults with normal facial profiles. *Korean J Orthod* 2013;43:178–85.
- Ozturk CN, Li Y, Tung R, Parker L, et al. Complications following injection of soft-tissue fillers. *Aesthet Surg J* 2013;33:862–77.
- Beleznay K, Humphrey S, Carruthers JD, Carruthers A. Vascular compromise from soft tissue augmentation: experience with 12 cases and recommendations for optimal outcomes. *J Clin Aesthet Dermatol* 2014;7:37–43.
- Alam M, Kakar R, Dover JS, Harikumar V, et al. Rates of vascular occlusion associated with using needles vs cannulas for filler injection. *JAMA Dermatol* 2021;157:174–80.
- Hanke CW, Higley HR, Jolivet DM, Swanson NA, et al. Abscess formation and local necrosis after treatment with Zyderm or Zyplast collagen implant. *J Am Acad Dermatol* 1991;25:319–26.
- Han J, He Y, Liu K, Yang Q. Necrosis of the glabella after injection with hyaluronic acid into the forehead. *J Craniofac Surg* 2018;29:e726–e727.
- Glaich AS, Cohen JL, Goldberg LH. Injection necrosis of the glabella: protocol for prevention and treatment after use of dermal fillers. *Dermatol Surg* 2006;32:276–81.
- Kang BK, Kang IJ, Jeong KH, Shin MK. Treatment of glabella skin necrosis following injection of hyaluronic acid filler using platelet-rich plasma. *J Cosmet Laser Ther* 2016;18:111–2.
- G Zambacos DH, Mandrekas A. Glabella impending skin necrosis: a case report. *Eur J Plast Surg* 2019;42:193–6.
- Osung K, Hyun C, Joonsoo P. Glabella: a susceptible area to tissue necrosis upon injection of hyaluronic acid filler. *Our Dermatol Online* 2018;9:82–3.
- Bowhay ASD, Soares DJ. Acute vascular compromise of the ophthalmic cutaneous angiosome after accidental self-injection of hyaluronic acid filler into the superficial temporal artery. *Dermatol Surg* 2021;47:1527–9.
- Bowhay ASD, Soares DJ. Acute vascular compromise of the ophthalmic cutaneous angiosome after accidental self-injection of hyaluronic acid filler into the superficial temporal artery. *Dermatol Surg* 2021;47:1527–9.
- Hong JH, Ahn SJ, Woo SJ, Jung C, et al. Central retinal artery occlusion with concomitant ipsilateral cerebral infarction after cosmetic facial injections. *J Neurol Sci* 2014;346:310–4.
- Hsiao SF, Huang YH. Partial vision recovery after iatrogenic retinal artery occlusion. *BMC Ophthalmol* 2014;14:120.
- Ansari ZA, Choi CJ, Rong AJ, Erickson BP, et al. Ocular and cerebral infarction from periocular filler injection. *Orbit* 2019;38:322–4.
- Hong DK, Seo YJ, Lee JH, Im M. Sudden visual loss and multiple cerebral infarction after autologous fat injection into the glabella. *Dermatol Surg* 2014;40:485–7.
- Beleznay K, Carruthers JD, Humphrey S, Jones D. Avoiding and treating blindness from fillers: a review of the world literature. *Dermatol Surg* 2015;41:1097–117.
- Beleznay K, Carruthers JDA, Humphrey S, Carruthers A, et al. Update on avoiding and treating blindness from fillers: a recent review of the world literature. *Aesthet Surg J* 2019;39:662–74.
- Sorensen EP, Council ML. Update in soft-tissue filler-associated blindness. *Dermatol Surg* 2020;46:671–7.
- Doyon VC, Liu C, Fitzgerald R, Humphrey S, et al. Update on blindness from filler: review of prognostic factors, management approaches, and a century of published cases. *Aesthet Surg J* 2024;44:1091–104.
- Khan TT, Colon-Acevedo B, Mettu P, DeLorenzi C, et al. An anatomical analysis of the supratrochlear artery: considerations in facial filler injections and preventing vision loss. *Aesthet Surg J* 2017;37:203–8.
- Lucaciu A, Samp PF, Hattingen E, Kestner RI, et al. Sudden vision loss and neurological deficits after facial hyaluronic acid filler injection. *Neurol Res Pract* 2022;4:40.
- Hansen JT, Netter FrankH. *Netter's Clinical Anatomy*. Philadelphia, PA: Saunders/Elsevier; 2010.
- Lee W. Prevention of hyaluronic acid filler-induced blindness. *Dermatol Ther* 2020;33:e13657.
- Carruthers JDA, Fagien S, Rohrich RJ, Weinkle S, et al. Blindness caused by cosmetic filler injection: a review of cause and therapy. *Plast Reconstr Surg* 2014;134:1197–201.
- Kim YS, Choi DY, Gil YC, Hu KS, et al. The anatomical origin and course of the angular artery regarding its clinical implications. *Dermatol Surg* 2014;40:1070–6.
- Ten B, Kara T, Kaya TI, Yilmaz MA, et al. Evaluation of facial artery course variations and depth by Doppler ultrasonography. *J Cosmet Dermatol* 2021;20:2247–58.
- Shen WW, Jiao CB, Ma JX, Xia YC, et al. Evaluation of facial artery course variations, diameters, and depth by Doppler ultrasonography. *J Plast Reconstr Aesthet Surg* 2023;84:79–86.
- Pils U, Anderhuber F, Neugebauer S. The facial artery—the main blood vessel for the anterior face? *Dermatol Surg* 2016;42:203–8.
- Gray HSS, Ellis H, Berkovitz BKB. *Gray's Anatomy: The Anatomical Basis of Clinical Practice* (39th ed). Edinburgh: Elsevier Churchill Livingstone; 2005.

37. Cotofana S, Alfertshofer M, Frank K, Bertucci V, et al. Relationship between vertical glabellar lines and the supratrochlear and supraorbital arteries. *Aesthet Surg J* 2020;40:1341–8.
38. Brennan C. Avoiding the “danger zones” when injecting neurotoxins. *Plast Surg Nurs* 2014;34:173–8; quiz 7-8.
39. Carruthers J, Carruthers A. Volumizing the glabella and forehead. *Dermatol Surg* 2010;36(Suppl 3):1905–9.
40. Guvenc U, Ten B, Kaya TI, Yuksek HH, et al. Evaluation of supratrochlear artery depth and course variations by Doppler ultrasonography along the glabellar frown lines for safer filler injections. *J Cosmet Dermatol* 2022;21:6717–26.
41. Vural E, Batay F, Key JM. Glabellar frown lines as a reliable landmark for the supratrochlear artery. *Otolaryngol Head Neck Surg* 2000;123:543–6.
42. Lee W, Moon HJ, Kim JS, Yang EJ. Safe glabellar wrinkle correction with soft tissue filler using Doppler ultrasound. *Aesthet Surg J* 2021;41:1081–9.
43. Tansatit T, Uruwan S, Rungsawang C. The crest injection technique for glabellar line correction and the paracentral artery. *Plast Reconstr Surg Glob Open* 2021;9:e3982.
44. Shumrick KA, Campbell A. Improvements in forehead flap design for nasal reconstruction. *Facial Plast Surg* 1998;14:165–71.
45. Kleintjes WG. Forehead anatomy: arterial variations and venous link of the midline forehead flap. *J Plast Reconstr Aesthet Surg* 2007;60:593–606.
46. Cong LY, Phothong W, Lee SH, Wanitphakdeedecha R, et al. Topographic analysis of the supratrochlear artery and the supraorbital artery: implication for improving the safety of forehead augmentation. *Plast Reconstr Surg* 2017;139:620e–7e.
47. Koziej M, Polak J, Holda J, TrybusHolda MM, et al. The arteries of the central forehead: implications for facial plastic surgery. *Aesthet Surg J* 2020;40:1043–50.
48. Phumyoo T, Jiirasutat N, Jitaree B, Rungsawang C, et al. Anatomical and ultrasonography-based investigation to localize the arteries on the central forehead region during the glabellar augmentation procedure. *Clin Anat* 2020;33:370–82.
49. Park HJ, Lee JH, Lee KL, Choi YJ, et al. Ultrasonography analysis of vessels around the forehead midline. *Aesthet Surg J* 2021;41:1189–94.
50. Cai B, Yuan R, Zhu GZ, Zhan WF, et al. Deployment of the ophthalmic and facial angiosomes in the upper nose overlaying the nasal bones. *Aesthet Surg J* 2021;41:NP1975–NP1985.
51. Liao ZF, Cong LY, Luo CE, Zhan WF, et al. New insight into glabellar arteries: a three-dimensional computed tomography and dissection study. *Plast Reconstr Surg* 2023;151:979–87.
52. Ismailoglu AV, Ismailoglu P, Aktekin M. Mapping the vascular and muscular topography of the glabellar region: implication for improving safety and efficacy of the glabellar injections. *Aesthet Plast Surg* 2024;48:1628–34.
53. Liao ZF, Cong LY, Li FW, Zhou YH, et al. Positions of the glabellar arteries: implications for glabellar injection. *Aesthet Plast Surg* 2023;47:2037–44.
54. Sclafani AP, Fagien S. Treatment of injectable soft tissue filler complications. *Dermatol Surg* 2009;35(Suppl 2):1672–80.
55. Stigall LE, Bramlette TB, Zitelli JA, Brodland DG. The paramidline forehead flap: a clinical and microanatomic study. *Dermatol Surg* 2016;42:764–71.
56. von Arx TTK, Yukiya O, Lozanoff S. The face—a vascular perspective. A literature review. *Swiss Dent J* 2018;14:382–92.